

CASE REPORT

## Granulomatous Inflammation of Gall Bladder

Nixon Dangol,<sup>1</sup> Ranga Bahadur Basnet<sup>1</sup>, Sharmila Parajuli<sup>1</sup>, Riti Amatya<sup>1</sup>

### ABSTRACT

Granulomatous cholecystitis is a condition affecting the gallbladder that is often confused with cancers and other types of cholecystitis, which poses a diagnostic challenge for medical professionals. We share a case of granulomatous cholecystitis in a 51-year-old man with resolving acute pancreatitis and hypertension. Imaging showed thickening of the gallbladder wall and presence of gallstones. Laparoscopic cholecystectomy was performed and histopathological examination confirmed that the patient had granulomatous cholecystitis, characterized by presence of epithelioid histiocytes and multinucleated giant cells. The case highlights the importance of considering granulomatous cholecystitis in the differential diagnosis of gallbladder diseases, especially in patients presenting with chronic inflammation and gallstones. This report underscores the need for high clinical suspicion to differentiate granulomatous cholecystitis from other gallbladder pathologies.

**Keywords:** Chronic inflammation, gallbladder granulomas, gallbladder tuberculosis, granulomatous cholecystitis

### INTRODUCTION

Granulomatous cholecystitis is a very rare gall bladder disease comprising of nodular inflammations called granulomas.<sup>1</sup> It often mimics other different gall bladder diseases, so exclusion of other pathologies often poses as a diagnostic challenge.<sup>2</sup> Several causes of granulomatous cholecystitis have been recorded in the literature so far, including infections, systemic diseases and irritants.<sup>3</sup> In regions where tuberculosis is endemic, tubercular cholecystitis should be thoroughly ruled out. Only 50 cases of granulomatous cholecystitis due to tuberculosis has been documented.<sup>4</sup> This paper describes a case of granulomatous cholecystitis with non-specific presentation, which emphasizes the need of comprehensive histological study for correct diagnosis.

### CASE PRESENTATION

A 51-year-old male, hypertensive patient developed sudden, moderate to severe, dull epigastric pain. There was no history of jaundice, bowel or bladder disturbances, fever, prominent family history or previous surgical interventions. The patient appeared fair, afebrile, and well-hydrated. The abdomen was soft, non-distended, non-tender with no guarding. Bowel sounds were present, and there was no evidence of ascites or palpable masses.

An abdominal ultrasound revealed mild fatty changes in the liver, multiple cholelithiasis with bulky pancreas showing a fuzzy outline and moderate ascites suggestive of acute pancreatitis. The Mantoux test was also observed to be non-reactive in the patient. The patient underwent laparoscopic cholecystectomy. Intra-operative findings included a normal liver surface. Approximately 700 mL of serous-colored

<sup>1</sup>Department of Pathology, Kathmandu Model Hospital, Pradarsani marg, Kathmandu, Nepal.

#### Corresponding author:

Dr. Nixon Dangol, Department of Pathology, Kathmandu Model Hospital, Pradarsani Marg, Kathmandu, Nepal.  
Email: [nixondangol@gmail.com](mailto:nixondangol@gmail.com) Phone: +977-9860152333

ascites was present. Adhesions between the omentum with gallbladder (GB) and abdominal wall was noted. Saponification was also noted in the abdominal wall. Upon receiving the specimen at pathology department, the specimen consisted of a regular walled GB with multiple yellow-colored stones, each measuring 2x2 cm.

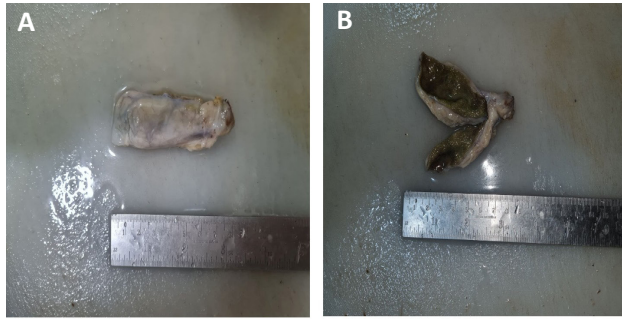


Figure 1. A) Gross specimen of gall bladder specimen measuring 7 cm x 2.5 cm with unremarkable external surface B) Cut section of gall bladder showing normal thickness with diffuse cholesterosis.

The gross description of the specimen revealed the gall bladder measuring 7x2.5 cm with unremarkable external surface (Figure 1A). Cut section showed the wall thickness to be 0.2 cm, and representative sections showed no stones but diffuse cholesterosis (Figure 1B).

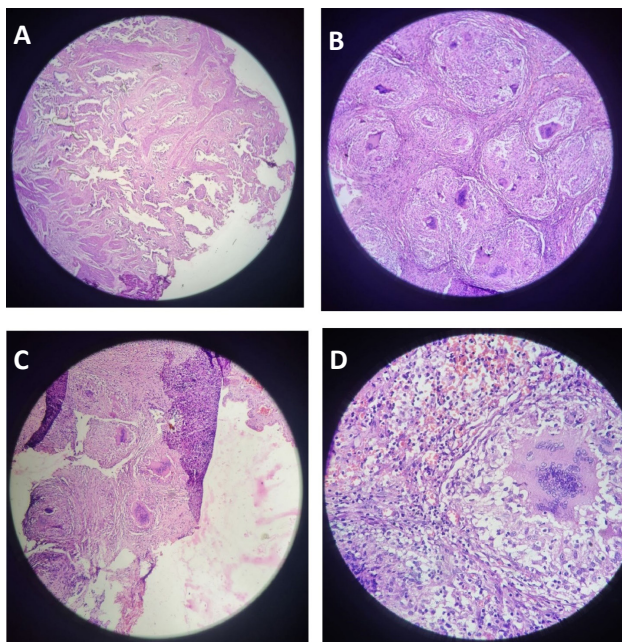


Figure 2. A) Histopathological examination of the gallbladder specimen revealed unremarkable mucosa with the presence of Rokitansky-Aschoff sinuses and Adenomyosis. (Hematoxylin and eosin stain; 4x) B) A good number of well formed caseating granulomas are seen. (Hematoxylin and eosin stain; 10x) C) Presence of multiple multinucleated giant cells, predominantly of the foreign body type along with epithelioid histiocytes. (Hematoxylin and eosin stain; 10x) D) Aggregates of lipid-laden macrophages with foreign body type of giant cell. (Hematoxylin and eosin stain; 40x)

The microscopic examination showed mucosa lined by columnar cells with basally located nuclei (Figure 2A). Aggregates of lipid-laden macrophages were present in the lamina propria, and the wall exhibited congestion with chronic inflammatory cell infiltrate, including lymphocytes, plasma cells, and macrophages (Figure 2D). Numerous well-defined non caseating granulomas were noted within the wall, comprising of Langhans and Foreign body type of giant cells, and epithelioid histiocytes (Figure 2B, 2C and 2D). The acid-fast stain was however found to be negative. Few benign glands were embedded in the muscularis propria (Figure 2A). Areas of fibrosis were also observed. There were no features of dysplasia or malignancy.

## DISCUSSION

Granulomatous inflammation of the gallbladder is a very rare condition, attributed to various causes, with tuberculosis being a common suspect in endemic regions. Other causes include infections, systemic diseases (such as sarcoidosis and Crohn's disease), and reactions to foreign bodies or irritants (such as gallstones and cholesterol crystals).<sup>3,5,6</sup>

Tuberculous cholecystitis results from hematogenous spread or direct extension of *Mycobacterium tuberculosis* (MTB) to the gallbladder leading to granuloma formation.<sup>7</sup> Epstein et al. reported that physiological concentrations of bile acids inhibit MTB growth in vitro, except for lithocholic acids, making the gallbladder a resilient site for harboring MTB.<sup>8</sup> Performing periodic acid-Schiff (PAS) and Ziehl-Neelsen (ZN) stains is crucial to exclude other infectious causes, as they significantly differ in the

course of treatment.

Patients with Granulomatous Cholecystitis often present with nonspecific symptoms such as abdominal pain, fever, and jaundice, which overlap with other gallbladder diseases.<sup>2,4</sup> At the time of operation, granulomatous inflammations often present as localized palpable indurations, which can be misinterpreted as neoplasms.<sup>3</sup> Radiological findings can be inconclusive, frequently mimicking gallbladder carcinoma, making preoperative diagnosis difficult.<sup>9</sup> This aligns with Zhanli et al who discussed cholesterol granuloma mimicking gall bladder carcinoma on PET/CT imaging.<sup>10</sup> Therefore, it is crucial to exclude other causes like gallbladder neoplasm, which shares close gross and radiological resemblances.

Definitive diagnosis typically requires histopathological examination of the resected gallbladder, revealing granulomatous inflammation.<sup>4</sup> There is little improvement in discrepancy rates between clinical and histological diagnoses from the 1960s to the present, of which 50 percent reveal unsuspected findings in biopsy.<sup>11</sup> Differentiation into histologic types based on the dominant form of histiocyte (e.g., xanthogranulomatous, pigmented, malakoplakic, histiocytic) has been recommended.<sup>3</sup> These various histologic types are attributed to the same pathological process, owing to the lipoid substances of bile in cases of biliary stasis and cystic duct obstruction.<sup>3</sup>

It is believed that mucosal flattening and the formation of Rokitansky-Aschoff sinuses, which invade the subserosal layer, act as a nidus for lithogenesis and ultimately granuloma formation.<sup>12</sup> In our case, the gallbladder did not show any nodular or diffuse thickening and was histologically consistent with the presence of epithelioid granulomas, foreign body giant cells, and foci of non-caseating necrosis. The rare incidence of granulomatous cholecystitis is often attributed to its poor documentation and non-specific presentation. It is advised that the absence or relative smallness of nodules, minimal or absent atypia, lack of mitosis, and recognition of bile deposits within a cellular lesion favor a benign course.<sup>3</sup>

## CONCLUSION

Granulomatous inflammation of the gallbladder is a

rare and under-documented condition with a diverse range of causes, including non-sinister conditions such as gallstones. The nonspecific clinical presentation highlights the critical need for meticulous histopathological examination to aid in accurate diagnosis and avoid mismanagement.

## REFERENCES

1. Rosai J. *Ackerman's surgical pathology*. 11th ed. St. Louis: Mosby; 2018. 865 p.
2. Khan R, Vasenwala SM, Arif SH, Harris SH. Granulomatous gall bladder: A surgico-pathological challenge. *Ann Saudi Med*. 2010 May-Jun;30(3):244. doi: 10.4103/0256-4947.62831. PMID: 20427945; PMCID: PMC2886880. [[PubMed](#)]
3. Hanada M, Tujimura T, Kimura M. Cholecystic granulomas in gallstone disease. A clinicopathologic study of 17 cases. *Acta Pathol Jpn*. 1981 Mar;31(2):221-31. PMID: 7257764. [[PubMed](#)]
4. Yu R, Liu Y. Gallbladder tuberculosis: case report. *Chin Med J (Engl)*. 2002 Aug;115(8):1259-61. PMID: 12515279 [[PubMed](#)]
5. Manes K, Chatzimargaritis K, Apessou D, Papastergiou V, Dervenis C. Granulomatous cholecystitis in a patient with schistosoma mansoni infection: A case report. *IJCRI*. 2014;5(6):439. doi:10.5348/ijcri-201484-CR-10395 [[PubMed](#)]
6. Handra-Luca A. Granulomatous Lithiasic Cholecystitis in Sarcoidosis. *Clin Pract*. 2016 Mar 31;6(1):811. doi: 10.4081/cp.2016.811. PMID: 27162601; PMCID: PMC4844810. [[PubMed](#)]
7. Valecha B. A Rare Case Report of Granulomatous Inflammation of Gall Bladder with Review of Literature. *SJPM*. 2019 Nov 30;04(11):846-8. doi: [10.36348/sjpm.2019.v04i11.013](https://doi.org/10.36348/sjpm.2019.v04i11.013) [[PubMed](#)]
8. Epstein D, Mistry K, Whitelaw A, Watermeyer G, Pettengell KE. The effect of physiological concentrations of bile acids on in vitro growth of Mycobacterium tuberculosis. *S Afr Med J*. 2012 May 23;102(6):522-4. doi: 10.7196/samj.5763. PMID: 22668954. [[PubMed](#)]
9. Ke QH, He ZL, Duan X, Zheng SS. Chronic cholecystitis with hilar bile duct stricture mimicking gallbladder carcinoma on positron emission

- tomography: A case report. *Mol Clin Oncol*. 2013 May;1(3):517-520. doi: 10.3892/mco.2013.93. Epub 2013 Mar 14. PMID: 24649203; PMCID: PMC3915913. [\[PubMed\]](#)
10. Fu Z, Chen X, Yang X, Li Q. Cholesterol Granuloma Masquerading as Gallbladder Carcinoma on 18F-FDG PET/CT. *Clin Nucl Med*. 2019 Jun;44(6):489-490. doi: 10.1097/RLU.0000000000002517. PMID: 30829860. [\[PubMed\]](#)
11. Roulson J, Benbow EW, Hasleton PS. Discrepancies between clinical and autopsy diagnosis and the value of post mortem histology; a meta-analysis and review. *Histopathology*. 2005 Dec;47(6):551-9. doi: 10.1111/j.1365-2559.2005.02243.x. PMID: 16324191. [\[PubMed\]](#)
12. Zaki M, Al-Refeidi A. Histological changes in the human gallbladder epithelium associated with gallstones. *Oman Medical Journal*. 2009 Oct 1;24(4):269-73. doi:10.5001/omj.2009.55 [\[PubMed\]](#)